

Cephalometrics

Cephalometry is the analysis and interpretation of standardized radiographs of the facial bones. In practice, cephalometrics has come to be associated with a true lateral view (Fig. 1). An antero-posterior radiograph can also be taken in the cephalostat, but this view is difficult to interpret and is usually only employed in cases with a skeletal asymmetry.

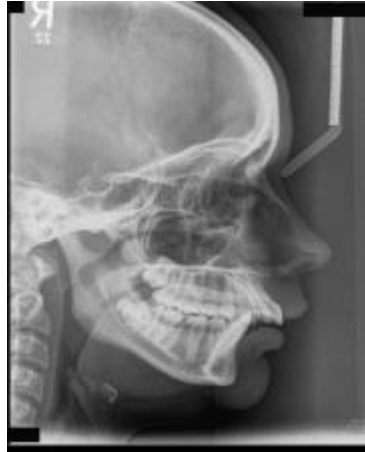

Fig.1 A lateral cephalometric radiograph. An aluminium wedge has been positioned to attenuate the beam thereby enhancing the view of the soft tissues.

INTRODUCTION Cephalometries had its beginning in craniometry. For many years anatomists and anthropologists were confined to measuring the craniofacial dimensions of skulls of dead individuals. This was not possible in case of living individuals, where the varying thickness of soft tissues interfered with the accuracy of these measurements. With the advent of radiography, an alternative method was provided which enabled the researchers to obtain indirectly but with sufficient accuracy, and convenience the skeletal measurements of the human skull. The reproducibility of these radiographs allowed for a longitudinal serial study of growth of living individuals.

The cephalostat: In order to be able to compare the cephalometric radiographs of one patient taken on different occasions, or those of different individuals, some standardization is necessary. To achieve this aim the cephalostat was developed by B. Holly Broadbent in the period after the First World War (Fig. 2). The cephalostat consists of an X-ray machine which is at a fixed distance from a set of ear posts designed to fit into the patient's external auditory meatus. Thus the central beam of the machine is directed towards the ear posts, which also serve to stabilize the patient's head. The position of the head in the vertical axis is standardized by ensuring that the patient's Frankfort plane (for definition see below) is horizontal. This can be done by manually positioning the subject or, alternatively, by placing a mirror some distance away level with the patient's head and asking him or her to look into their own eyes. This is

termed the natural head position, and some orthodontists claim that it is more consistent than a manual approach. It is normal practice to cone down the area exposed so that the skull vault is not routinely included in the X-ray beam.



Fig. 2 :Cephalostat

Unfortunately, attempts to standardize the distances from the tube to the patient (usually between 5 and 6 feet (1.5 to 1.8 m)) and from the patient to the film (usually around 1 foot (around 30 cm)) have not been entirely successful as the values in parentheses would suggest. Some magnification, usually of the order of 7–8 per cent, is inevitable with a lateral cephalometric film. In order to be able to check the magnification and thus the comparability of different films, it is helpful if a scale is included in the view. In order to allow comparisons between radiographs of the same patient it is essential that the magnification for a particular cephalostat is standardized.

Indications for cephalometric evaluation: An increasing awareness of the risks associated with X-rays has led clinicians to re-evaluate the indications for taking a cephalometric radiograph

- 1- An aid to diagnosis It is possible to carry out successful orthodontic treatment without taking a cephalometric radiograph, particularly in Class I malocclusions. However, the information that cephalometric analysis yields is helpful in assessing the probable aetiology of a malocclusion and in planning treatment. The benefit to the patient in terms of the additional information gained must be weighed against the X-ray dosage. Therefore a lateral cephalometric radiograph is best limited to patients with a skeletal discrepancy and/or where anteroposterior movement of the incisors is planned. In a small proportion of patients it may be helpful to monitor growth to aid the planning and timing of treatment by taking serial cephalometric radiographs, although again the dosage to the patient must be

justifiable. In addition, a lateral view is often helpful in the accurate localization of unerupted displaced teeth and other pathology.

- 2- A pre-treatment record A lateral cephalometric radiograph is useful in providing a baseline record prior to the placement of appliances, particularly where movement of the upper and lower incisors is planned.
- 3- Monitoring the progress of treatment In the management of severe malocclusions, where tooth movement is occurring in all three planes of space (for example treatments involving functional appliances, or upper and lower fixed appliances), it may be helpful to take a lateral cephalometric radiograph during treatment to monitor incisor inclinations and anchorage requirements A lateral cephalometric radiograph may also be useful in monitoring the movement of unerupted teeth and for assessing upper incisor root resorption if this is felt to be a potential risk during treatment.
- 4- Research purposes A great deal of information has been obtained about growth and development by longitudinal studies which involved taking serial cephalometric radiographs from birth to the late teens or beyond. While the data provided by previous investigations are still used for reference purposes, it is no longer ethically possible to repeat this type of study. However, those views taken routinely during the course of orthodontic diagnosis and treatment can be used to study the effects of growth and treatment.

Evaluating a cephalometric radiograph

Before starting a tracing it is important to examine the radiograph for any abnormalities or pathology. For example, a pituitary tumour could result in an increase in the size of the sella turcica. A lateral cephalometric view is also helpful in assessing the patency of the airway, as enlarged adenoids can be easily seen. A lateral skull radiograph should be hand-traced in a darkened room with suitable back illumination using a hard pencil and high-quality tracing paper attached to the radiograph. The peripheral regions of the radiograph should be masked to highlight the cranial base and facial complex. Bilateral structures should be traced independently and then averaged. Alternatively, the landmarks and tracing can be digitized directly into a computer using specialized software, which will instantly produce an analysis

Computer-based cephalometric analysis: The advent of personal computing has resulted in the development of many commercial and freely available software packages that allow the digitization and manipulation of imported cephalometric lateral skull radiographs (Fig.3). Although landmark identification is still largely under control of the user, measurement error is significantly reduced because the software carries it out. However, the main advantage of these

programmes is versatility they provide, allowing the user to generate numerous different analyses or even customize their own. In addition, they can perform superimpositions, undertake prediction planning for treatment outcome and are extremely useful for planning orthognathic surgery, with superimposition of profile photographs onto the cephalometric tracing allowing the prediction of soft tissue changes associated with surgical jaw movements. Studies have shown digitizing to be as accurate as tracing a radiograph by hand and with the increasing use of digital radiographs this now becoming the normal.

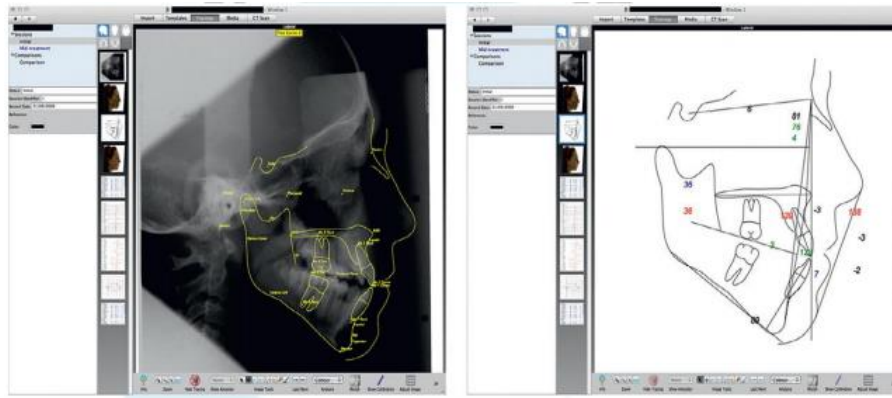


Figure 3: QuickCeph® computer-prediction software for cephalometric planning

Commonly used cephalometric points and reference lines The points and reference lines are shown in Fig.(4) .

Sella (S): The midpoint of the sella turcica.

Nasion (N): The most anterior point on the frontonasal suture. When difficulty is experienced locating nasion, the point of deepest concavity at the intersection of the frontal and nasal bones can be used instead.

Orbitale (Or): The most inferior anterior point on the margin of the orbit. By definition, the left orbital margin should be used to locate this point. However, this can be a little tricky to determine radiographically, and so an average of the two images of left and right is usually taken.

Porion (Po): The uppermost outermost point on the bony external auditory meatus. This landmark can be obscured by the ear posts of the cephalostat, and some advocate tracing these instead. However, this is not recommended as they do not approximate to the position of the external auditory meatus. The uppermost surface of the condylar head is at the same level, and this can be used as a guide where difficulty is experienced in determining porion.

A Point (A): This is the point of deepest concavity on the anterior profile of the maxilla. It is also called subspinale. This point is taken to represent the anterior limit of the maxilla and is often tricky to locate accurately. However, tracing the outline of the root of the upper central incisor first and shielding all extraneous light often aids identification. A point is located on alveolar bone and is liable to changes in position with tooth movement and growth.

Anterior nasal spine (ANS): This is the tip of the anterior process of the maxilla and is situated at the lower margin of the nasal aperture.

Posterior nasal spine (PNS): This is the tip of the posterior nasal spine of the maxilla. This point is often obscured by the developing third molars, but lies directly below the pterygomaxillary fissure.

B point (B): The point of deepest concavity on the anterior surface of the mandibular symphysis. B point is also sited on alveolar bone and can alter with tooth movement and growth.

Gonion (Go): The most posterior inferior point on the angle of the mandible. This point can be 'guesstimated', or determined more accurately by bisecting the angle formed by the tangents from the posterior border of the ramus and the inferior border of the mandible

Menton (Me): The lowest point on the mandibular symphysis.

Pogonion (Pog): The most anterior point on the mandibular symphysis.

SN line: This line, connecting the midpoint of sella turcica with nasion, is taken to represent the cranial base.

Frankfort plane: This is the line joining porion and orbitale. This plane is difficult to define accurately because of the problems inherent in determining orbitale and porion.

Maxillary plane (Palatal plane): The line joining anterior nasal spine with posterior nasal spine. Where it is difficult to determine ANS and PNS accurately, a line parallel to the nasal floor can be used instead.

Functional occlusal plane: A line drawn between the cusp tips of the permanent molars and premolars (or deciduous molars in mixed dentition). It can be difficult to decide where to draw this line, particularly if there is an increased curve of Spee, or only the first permanent molars are in occlusion during the transition from mixed to permanent dentition. The functional plane

can change orientation with growth and/or treatment, and so is not particularly reliable for longitudinal comparisons.

Mandibular plane: The line joining gonion and menton. This is only one of several definitions of the mandibular plane, but is probably the most widely used.

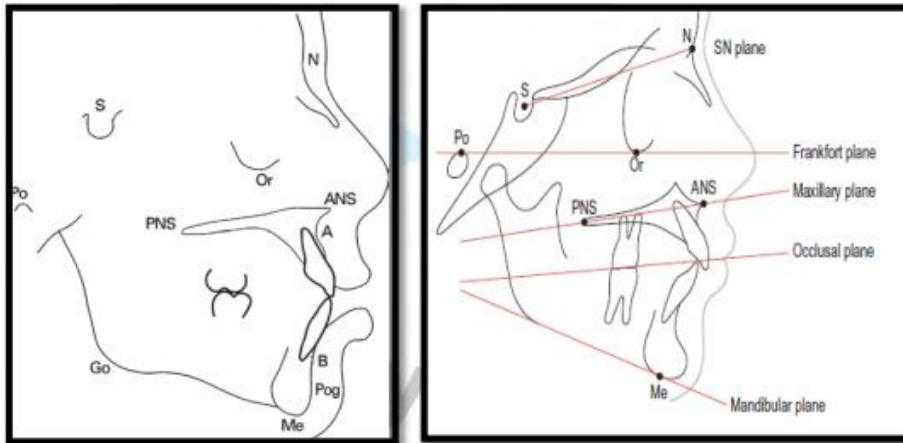


Fig.4: Commonly used cephalometric points and planes

Assessing the vertical skeletal relationship

The vertical jaw relationship can also be assessed in a number of ways (Fig.5):

1- Maxillary–mandibular plane angle (MMPA) The MMPA is a common method for evaluating the vertical jaw relationship, with horizontal reference planes that are easily located. The mean value is $27^\circ \pm 5^\circ$.

2- Frankfort–mandibular plane angle (FMPA) The FMPA uses the Frankfort plane as a horizontal reference to the mandibular plane. This method ignores the maxillary plane, which if affected by a significant cant can give a misleading value to the vertical jaw relationship. It is useful to use this measurement in conjunction with the MMPA plane angle. The mean value is $27^\circ \pm 5^\circ$.

3- Anterior and posterior face heights Anterior and posterior face heights are also used as a measure of vertical facial relationships (Fig.6):

4- Total Anterior Face Height (TAFH) extends from nasion to menton, with both lines constructed perpendicular to the maxillary plane (mean 119 mm in an adult male). TAFH is further subdivided into:

5- **Upper anterior face height (UAFH);** nasion to maxillary plane (mean 54 mm);

6- Lower anterior face height (LAFH); maxillary plane to menton (mean 65 mm); and

7- Total Posterior Face Height (TPFH) extends from sella to gonion, with both lines constructed perpendicular to the maxillary plane (mean 79 mm in an adult male). TPFH is therefore subdivided into:

8- Upper posterior face height (UPFH); sella to maxillary plane (mean 46 mm);

9- Lower posterior face height (LPFH); maxillary plane to gonion (mean 33 mm); And

- The TPFH should be approximately 65% of the TAFH. It should be noted that the TPFH (unlike the TAFH) is influenced by a particularly superior or inferior position of sella and this will affect the TPFH/TAFH ratio. Referring to the SN–maxillary plane angle can cheque the relative position of sella within the cranium.

- The LAFH should be approximately 55% of the TAFH.

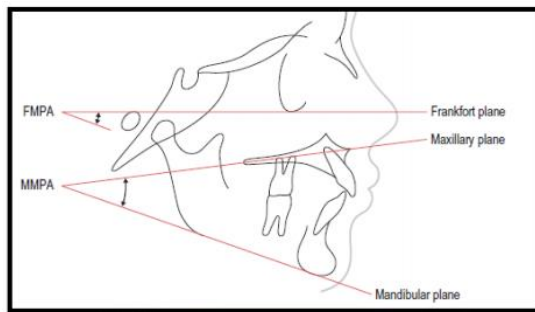


Figure 5: Vertical facial relationships. FMPA, Frankfort–mandibular plane angle; MMPA, maxillary– mandibular plane angle.

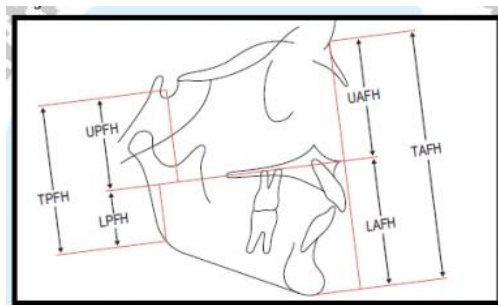
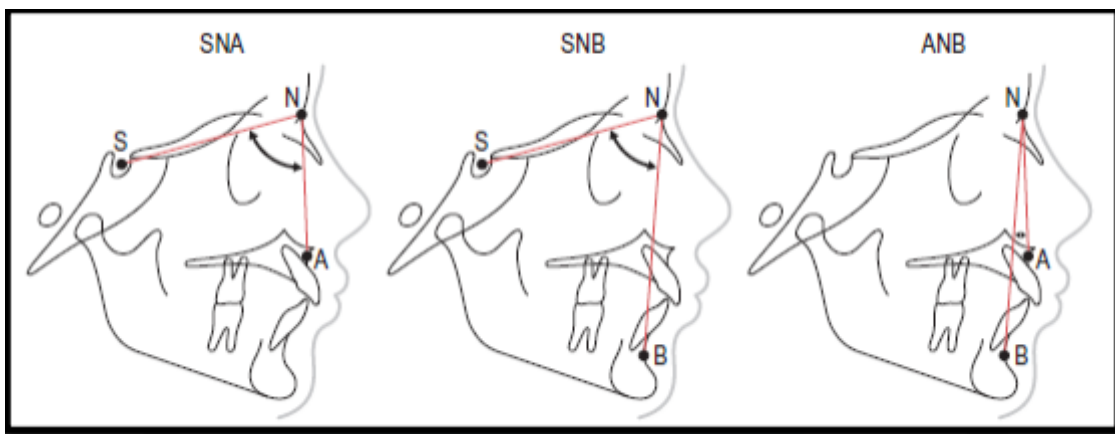


Figure 6: Face heights. LAFH, lower anterior face height; LPFH, lower posterior face height; TAFH, total anterior face height; TPFH, total posterior face height; UAFH, upper anterior face height; UPFH, upper posterior face height

Assessment of Anteroposterior skeletal pattern

1- Angle ANB: In order to be able to compare the position of the maxilla and mandible, it is necessary to have a fixed point or plane. The skeletal pattern is often determined cephalometrically by comparing the relationship of the maxilla and mandible with the cranial base by means of angles SNA (81 ± 3) and SNB (78 ± 3). The difference between these two measurements, angle ANB, is classified broadly as follows:

ANB < 2° = Class III, 2° - 4° = Class I, ANB > 4° = Class II



If SNA is increased or reduced from the average value, this could be due to either a discrepancy in the position of the maxilla (as indicated by point A) or nasion. The following (rather crude) modification is often used in order to make allowance for this: Provided the angle between the maxillary plane and the sella–nasion line is within 5–11°: • if SNA is increased, for every degree that SNA is greater than 81°, subtract 0.5° from ANB; • if SNA is reduced, for every degree that SNA is less than 81°, add 0.5° to ANB. If the angle between the maxillary plane and the sella–nasion line is not within 5–11°, this correction is not applicable.

2- Ballard conversion: This analysis uses the incisors as indicators of the relative position of the maxilla and mandible. It is easy to confuse a Ballard conversion and a prognosis tracing (Fig.7), but in the former the aim is to tilt the teeth to their normal angles (thus eliminating any dento-alveolar compensation) with the result that the residual overjet will indicate the relationship of the maxilla to the mandible.

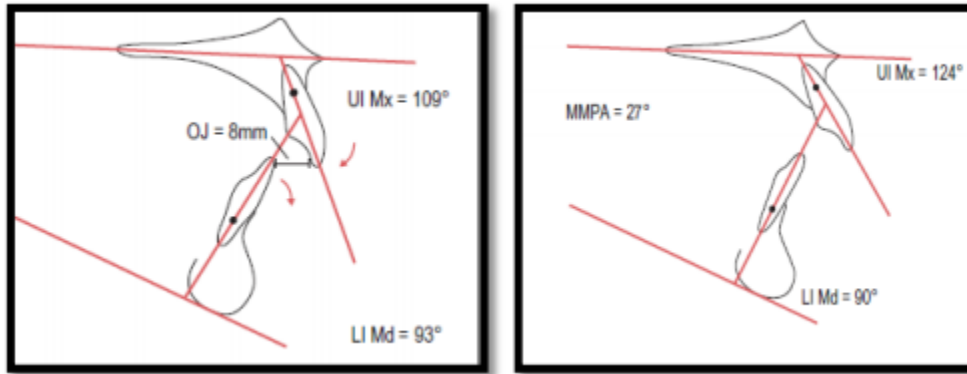


Figure .7: Ballard's conversion tracing. In the upper tracing, the UI to maxillary plane angle is 124° , whilst the LI to mandibular plane is 90° . The normal values should be 109° and 93° respectively (the lower ncisor to mandibular plane value is calculated by subtracting the maxillary–mandibular plane angle (MMPA) from 120°). By adjusting these teeth to their normal values around a fulcrum approximately one-third of the root length from the apices, it can be seen that the overjet is still increased and therefore the skeletal pattern is class II.

3- Wits analysis This analysis compares the relationship of the maxilla and mandible with the occlusal plane. There are several definitions of the occlusal plane, but for the purposes of the Wits analysis it is taken to be a line drawn between the cusp tips of the molars and premolars (or deciduous molars), which is known as the functional occlusal plane. Perpendicular lines from both point A and point B are dropped to the functional occlusal plane to give points AO and BO. The distance between AO and BO is then measured. The mean values are 1 mm (SD ± 1.9 mm) for males and 0 mm (SD ± 1.77 mm) for females (Fig. 8). The main drawback to the Wits analysis is that the functional occlusal plane is not easy to locate, which obviously affects the accuracy and reproducibility of the Wits analysis. A slight difference in the angulation of the functional occlusal plane can have a marked effect on the relative positions of AO and BO.

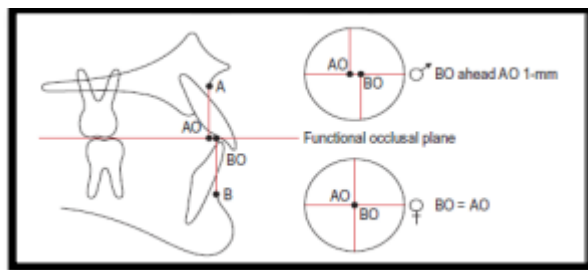


Figure (8): Wits method. Perpendicular lines are dropped from A and B points to the functional occlusal plane. For males BO should lie 1 mm ahead of AO, whilst for females AO and BO should coincide. In a skeletal class II, AO lies ahead of BO, whilst in a class III discrepancy, BO is significantly ahead of AO.

Assessing the dental relationship Several methods of assessment are available for positioning the maxillary and mandibular dentition in relation to the jaws and face.

1- Maxillary incisor relationship: The inclination of the most prominent maxillary incisor is constructed using a line through long axis of upper incisor and measured in relation to the maxillary plane (Fig. 9). The mean value is $109^\circ \pm 6^\circ$.

2- Mandibular incisor relationship: The inclination of the most prominent mandibular incisor is constructed using a line through long axis of lower incisor and measured in relation to the mandibular plane. The mean value is $93^\circ \pm 6^\circ$; however, mandibular incisor inclination can be influenced by orientation of the mandibular plane. As the mandibular plane becomes steeper, the incisors will tend to retrocline. An alternative method of evaluating the correct mandibular incisor relationship is to subtract the MMPA from 120.

3- Interincisal angle: The interincisal angle is the angle formed between the most prominent maxillary and mandibular incisors . The mean value is $135^\circ \pm 10^\circ$.

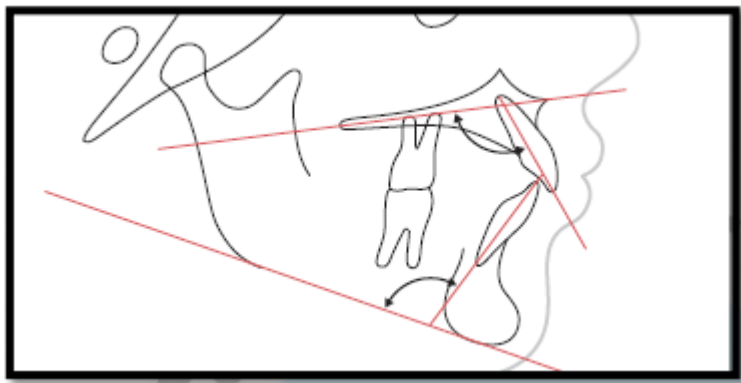


Figure 9: Incisor relationships.

A sample of cephalometric tracing

SNA	$81^\circ \pm 3^\circ$
SNB	$78^\circ \pm 3^\circ$
ANB	$3^\circ \pm 2^\circ$
SN Mx plane	$8^\circ \pm 3^\circ$
WITS	BO + 1 mm ahead AO (males) BO = AO (females)
MMPA	$27^\circ \pm 5^\circ$
UI Mx plane	$109^\circ \pm 6^\circ$
LI Md plane	$93^\circ \pm 6^\circ$
VI	$135^\circ \pm 10^\circ$
LI APo	1 ± 2 mm
TAFH	Mean 119 mm
UAFH	Mean 54 mm
LAFH	Mean 65 mm
% LAFH	Mean 55%
NLA	$100^\circ \pm 8^\circ$
Lip relation to E-line	Upper -4 mm Lower -2 mm

SNA, angle SN (sella-nasion) to point A; SNB, angle SN to point B; ANB, difference between angles SNA and SNB; SN Mx plane, SN-maxillary plane angle; MMPA, maxillary-mandibular plane angle; UI Mx plane, upper incisor-maxillary plane angle; LI Md plane, lower incisor-mandibular plane angle; VI, interincisal angle; LI APo, distance from lower incisor tip to A-Pog line; TAFH, total anterior face height; UAFH, upper anterior face height; LAFH, lower anterior face height; NLA, nasolabial angle.

Soft tissue analysis This is particularly important in diagnosis and planning prior to orthognathic surgery. As with other elements of cephalometric analysis, there are a large number of different analyses of varying complexity. The following are some of the more commonly used.

- 1- The Holdaway line: This is a line from the soft tissue chin to the upper lip. In a well-proportioned face this line, if extended, should bisect the nose (Fig.10).
- 2- Rickett's E-plane: This line joins the soft tissue chin and the tip of the nose. In a balanced face the lower lip should lie 2 mm (± 2 mm) posterior to this line with the upper lip positioned a little further posteriorly to the line (Fig.10).
- 3- Facial plane: The facial plane is a line between the soft tissue nasion and the soft tissue chin. In a well-balanced face the Frankfort plane should bisect the facial plane at an angle of about 86° and point A should lie on it (Fig.10). As with other aspects of cephalometrics, but perhaps more pertinently, these analyses should be supplementary to

a clinical examination, and it should also be remembered that beauty is in the eye of the beholder.

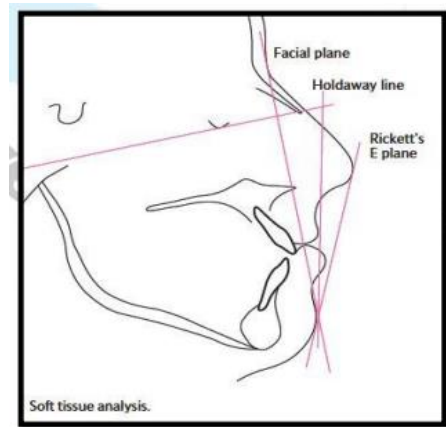


Fig. 10:Soft tissue analyses

Prognosis tracing: Sometimes it is helpful to be able to determine the type and amount of incisor movement required to correct an increased or reverse overjet. Although the skeletal pattern will give an indication, on occasion compensatory proclination or retroclination (known as dento-alveolar compensation) of the incisors, can confuse the issue. When planning treatment in such a case it may be helpful to carry out a prognosis tracing. This involves ‘moving’ the incisor(s) to mimic the movements achievable with different treatment approaches to help determine the best course of action for that patient .