

Parasitology

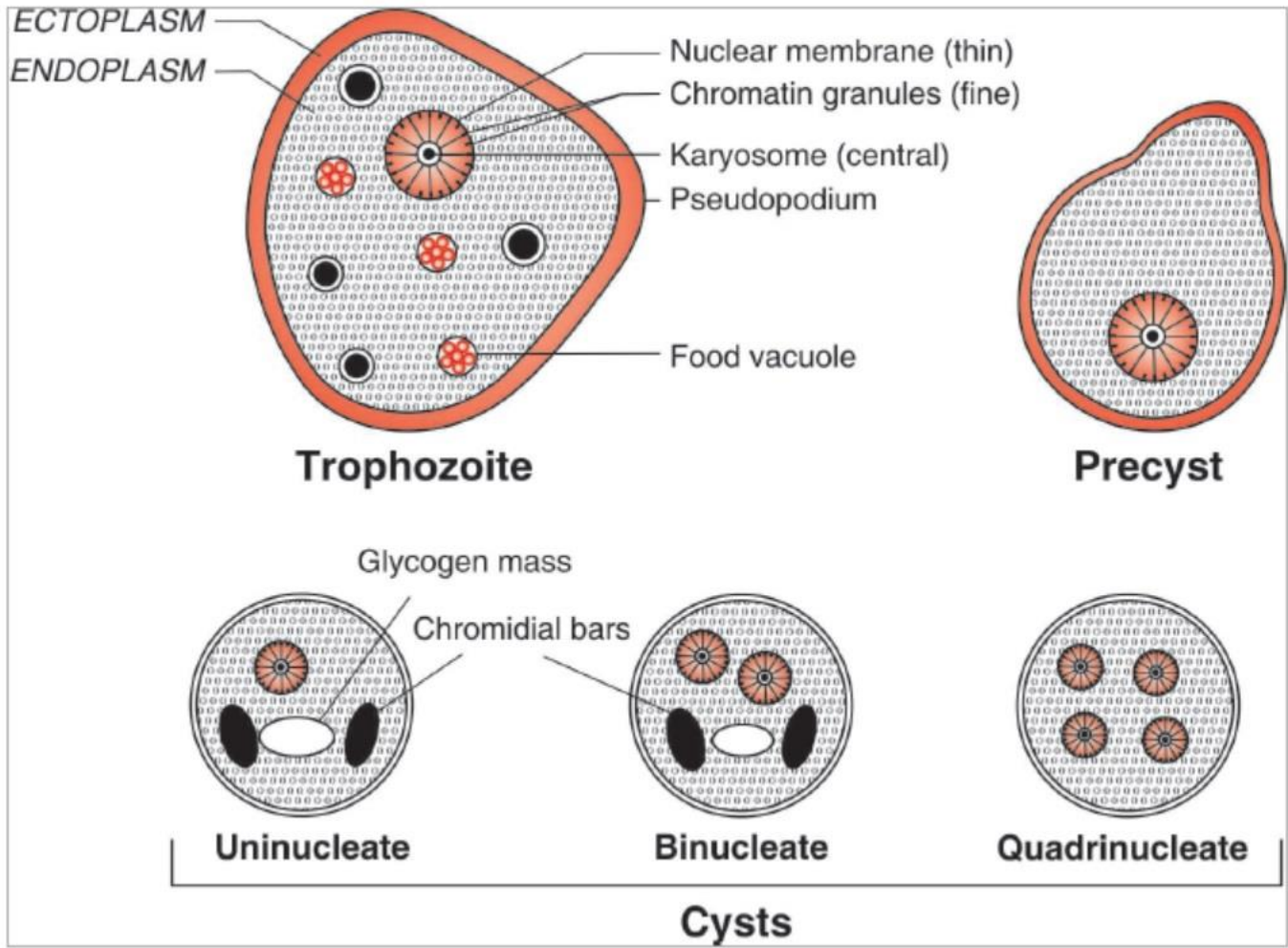
Lab 2

AL-Farahidi University / college of pharmacy / second
stage

2022-2023

Entamoeba histolytica

- **Morphology:** the parasite exists in three forms; trophozoite, precyst and cyst.
- **Trophozoites;** 10-60 μm size, unidirectional motility, single pseudopodium, ingest erythrocytes, granular cytoplasm small, central karyosome, and achromatic fibrils (having spoke-like radial arrangement).
- **Habitat:** trophozoites reside in mucosa and submucosa of large intestine of man.
- **Precyst;** It is smaller in size, varying from 10–20 μm in diameter. It is oval with a blunt pseudopodium projecting from the periphery. Food vacuoles disappear. There is no change in the nucleus which shows characteristics of the trophozoite.



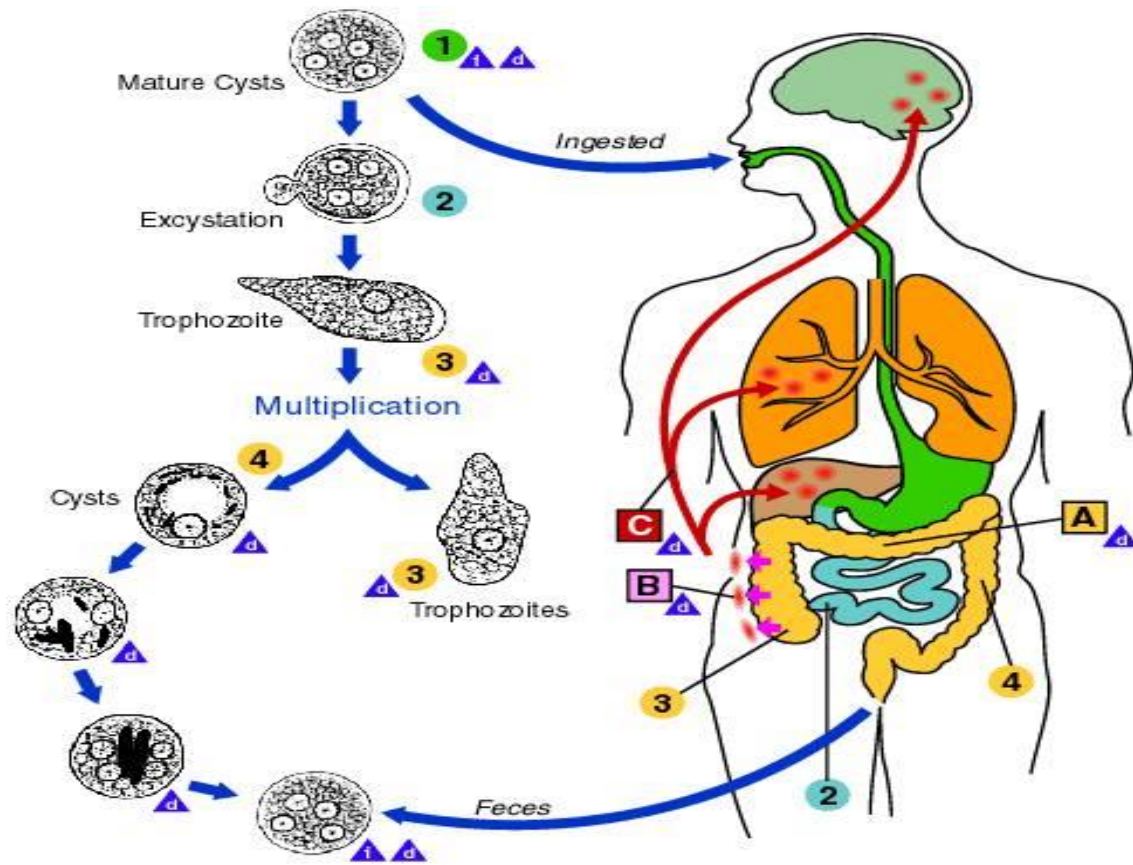
- **Life cycle:**
- Infection by *E. histolytica* occurs by ingestion of mature cysts (quadrinucleate) in faecally contaminated food, water, or hands.
- Excystation occurs in the small intestine and trophozoites are released, which migrate to the large intestine.
- The trophozoites multiply by binary fission and produce cysts, and both stages are passed in the feces.

- **Trophozoites passed in the stool are rapidly destroyed once outside the body, and if ingested would not survive when exposed to the gastric environment**
- **In contrast, cysts may remain viable in a humid environment and stay infective for several days.**
- **In the small intestine the cyst wall is lysed by trypsin and a single tetranucleate amoeba (metacyst) is liberated. Each nucleus divides by binary fission giving rise to eight nuclei, thus from each mature cyst eight small metacystic trophozoites are produced. This process is known as excystation.**

- **Metacystic trophozoites are carried in the faecal stream into the caecum. They invade the mucosa and ultimately lodge in the submucous tissue of large intestine. Here they grow and multiply by binary fission. During growth, *E. histolytica* secretes a proteolytic enzyme which brings about destruction and necrosis of tissue and produces flask- shaped ulcers.**

- **Encystation:** occurs in the intestinal lumen in which chromatin materials are concentrated into bars (chromatoidal bodies) in the cytoplasm of the cyst. The nucleus of cyst divides into two, then each of the two daughter nuclei divided once again so mature cyst has four nuclei. The amoebae are mostly present at the periphery of the lesion. A large number of trophozoites are excreted along with blood and mucus in the stool leading to amoebic dysentery.

- **In a few cases, erosion of the large intestine may be so extensive that trophozoites gain entrance into the radicles of portal vein and are carried away to the liver where they multiply leading to amoebic hepatitis and amoebic liver abscess.**



i = Infective Stage
 d = Diagnostic Stage

A = Non Invasive Colonization
B = Intestinal Disease
C = Extra-Intestinal Disease

Pathogenesis of *Entamoeba histolytica*

- **Intestinal amoebiasis:** After an incubation period of 1-4 weeks, the amoeba invade colonic mucosa. During growth, *E. histolytica* secretes proteolytic enzymes, producing flask-shaped ulcers and profuse bloody diarrhea (amoebic dysentery). Ulcers may be deep or superficial.
- *E. histolytica* may also cause amoebic appendicitis and amoebomas (pseudotumoral lesions associated with necrosis, inflammation and oedema).

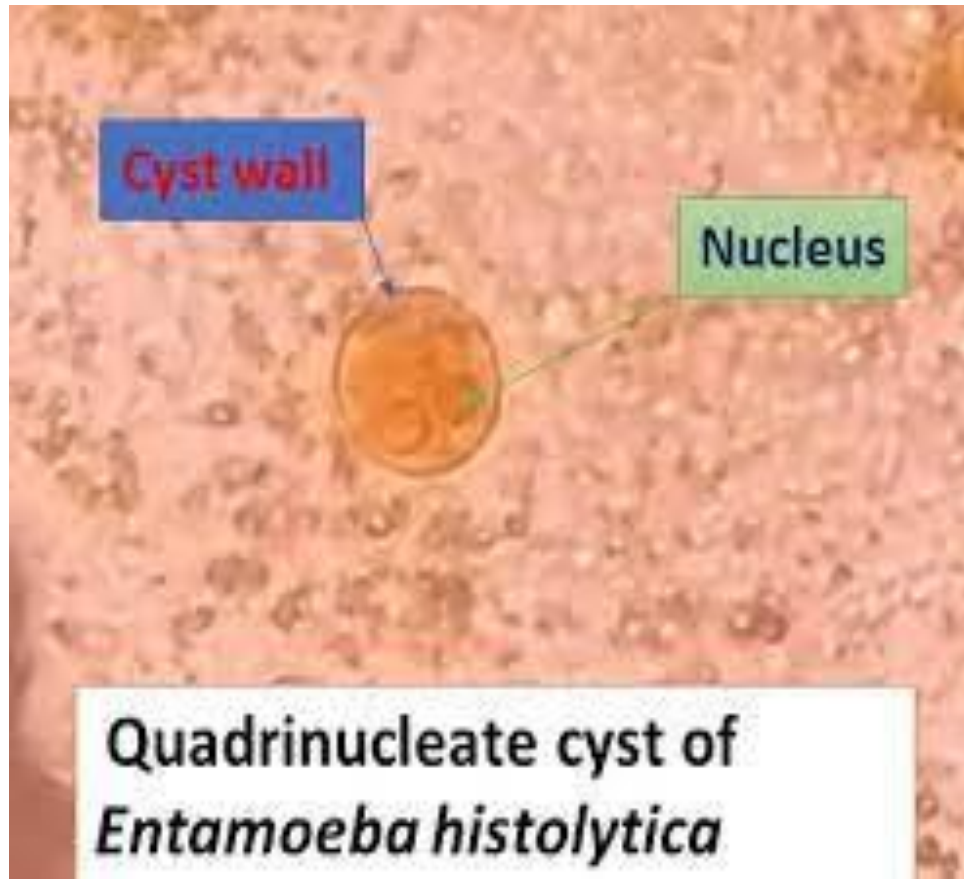
- **Extraintestinal amoebiasis:** About 5-10% individuals with intestinal amoebiasis, 1-3 months after disappearance of dysentery, develop hepatic amoebiasis. Trophozoites are carried from the ulcer in the large intestine and multiply in the liver, lead to cytolytic action then small abscesses merge to form big liver abscesses. The abscesses may grow in various directions; it may enter into general circulation involving lungs, brain, spleen, skin, etc.

Symptoms

- **Fever, chills, and diarrhea, sometimes bloody or white mucus and often with cramps. Some people may have only mild abdominal discomfort or no symptoms at all. Symptoms can start 2 or more weeks after infection.**

Laboratory Diagnosis

- **Microscopic identification of cysts and trophozoites in the stool is the common method for diagnosing *E. histolytica*. This can be accomplished using wet mount and permanently stained preparations as Iodine or trichrome or by Flotation or Sedimentation method for stool samples.**
- **-Blood examination: shows moderate leukocytosis.**



- **Serological tests:** in later stages of invasive amoebiasis, antibodies appear. Tests include ELISA, IHA (indirect hemagglutination test) and IFA (immunofluorescent antibody test).
- **-Histology:** trophozoites can be identified in aspirates or biopsy samples obtained during colonoscopy or surgery.
- **- Molecular methods:** DNA probe and PCR.

Treatment

- **For asymptomatic infections, paromomycin or iodoquinol are the drugs of choice. For symptomatic intestinal or extraintestinal infections, the drugs of choice are metronidazole or tinidazole, immediately followed by treatment with paromomycin or iodoquinol.**

Opportunistic amoebae

- It is a free-living amoeba that can be pathogenic, causing a fulminant brain infection called naegleriasis.
- Found in warm freshwater and in the soil near warm-water discharges of industrial plants, and in unchlorinated or minimally-chlorinated swimming pools.
- It can be seen in either an amoeboid or temporary flagellate stage. *N. fowleri* is inhaled through the nose, where it then enters the nasal and olfactory nerve tissue, travelling to the brain.
- *N. fowleri* normally eat bacteria, but when it enters humans, it uses the brain as a food source.

- **The amoeboid form of *N. fowleri* is the invasive stage of the parasite. Man acquires infection by nasal contamination during swimming in freshwater lakes, ponds or swimming pools. Infection may also be acquired by inhalation of dust containing infective forms. It is likely that flagellate forms or cysts of *N. fowleri* could enter the nose. However, since the amoeboid form is the invasive stage of the parasite, therefore, it appears that flagellate forms revert to amoeboid forms and the amoeboid forms escape from the cysts in the nose.**

- **Patient develops severe frontal headache, fever (39°–40°C), anorexia, nausea, vomiting and signs of meningeal irritation. Involvement of the olfactory lobes may lead to disturbances in smell or taste. Patient may also develop visual disturbances, confusion, irritability, seizures and coma. The disease usually results in death within 72 hours of the onset of symptoms.**
- **The period between contact with the organism and onset of clinical symptoms vary from 2–3 days to as long as 7–15 days.**

Treatment

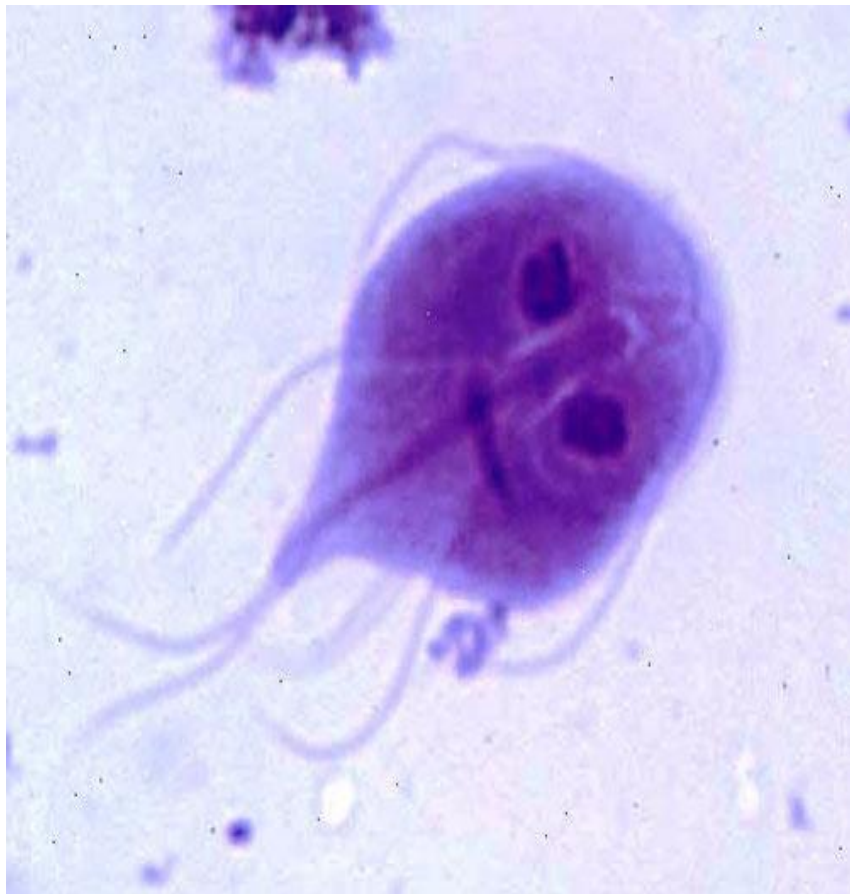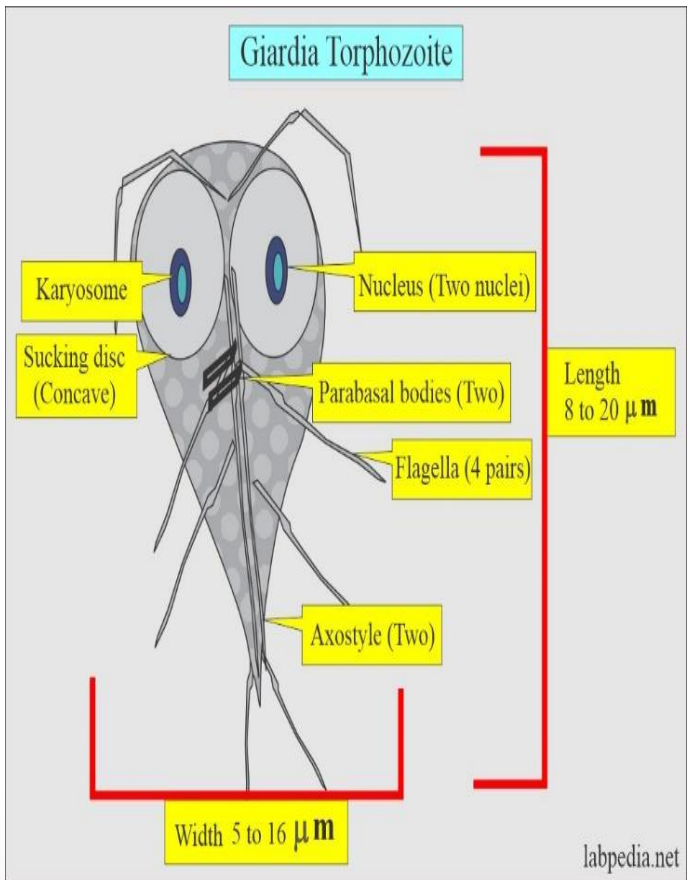
- **Amphotericin B, a drug of considerable toxicity, is the antinaeplial agent for which there is evidence of clinical effectiveness.**

Intestinal, oral and genital flagellates

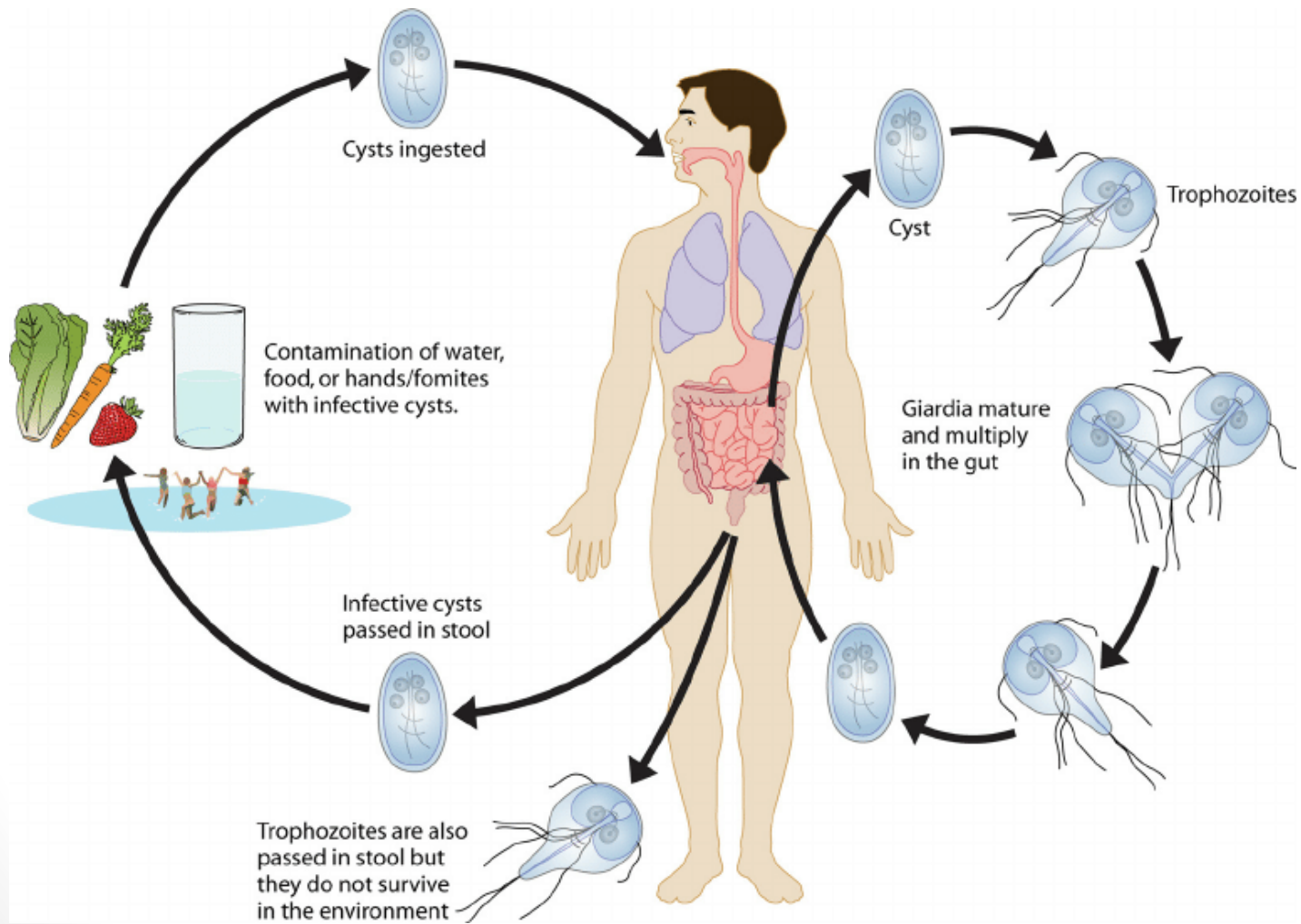
- **Giardia lamblia** (*G. duodenalis*; *G. intestinalis*)
- Giardia was discovered by Leeuwenhoek in 1681 in his own stool but was not described until 1859 by Lambl. *Giardia lamblia* is a cosmopolitan parasite. The highest prevalence of *G. lamblia* occurs in tropics and subtropics where sanitation is poor. Infections seem to be more common in children than adults.
- Habitat: It inhabits duodenum and the upper part of jejunum of man.
- Morphology: It exists in two forms:
 - 1. Trophozoite
 - 2. Cyst

Giardia lamblia Life Cycle

- **Life cycle:** It passes its life cycle in a single host, the man. No intermediate host is required. Mature cyst is the infective form of the parasite. Man acquires infection by ingestion of cysts in faecally contaminated water or food. Infection may occur through ingestion of as few as 10–25 cysts. Infection may also be acquired by anal-oral sexual practices among male homosexuals. Within 30 minutes of ingestion excystation occurs in the duodenum. The cyst hatches out two trophozoites, which then multiply by binary fission to form enormous numbers and colonize in the duodenum and upper part of jejunum. To avoid acidity of duodenum, it may localize in biliary tract.



- **By means of the concavity on its ventral surface the trophozoite attaches to the mucosal surface of the duodenum and jejunum. In frankly diarrhoeic stools, it is usual to find only the trophozoites. Encystation occurs commonly in transit down the colon where the intestinal contents lose moisture and patient starts passing formed stools. The trophozoites retract the flagella into the axonemes, the cytoplasm becomes condensed and a thin tough hyaline cyst wall is secreted. As the cyst matures, the internal structures are doubled, so that when excystation occurs, the cytoplasm divides, thus producing two trophozoites.**



Laboratory diagnosis

- 1. Giardiasis** can be diagnosed by identification of cysts of *G. lamblia* in the formed stools and the trophozoites of the parasite in diarrhoeal stools through general stool examination (GSE) under light microscope.
- 2. Anti-Giardia antibodies**, in the patient serum, may be detected by ELISA and indirect fluorescent antibody tests. However, these may indicate present or past infection.
- 3. Enterotest** (string test): aspirate specimens from the upper intestine by swallow a gelatin capsule, contains a spool of nylon string, to help it go down into stomach then (after 4-6 hrs.), the string will be pulled back up out of stomach through the throat and examined under a microscope.
- 4. Biopsy**: After multiple stool examinations, examination of bile aspirated from duodenum and Enterotest are negative, biopsy from multiple duodenal and jejunal sites may confirm the diagnosis of giardiasis.

Treatment

- **Metronidazole is an antibiotic that can cause nausea.**
- **- Tinidazole often treats giardiasis in a single dose and is as effective as metronidazole.**
- **- Furazolidone is a popular option for children.**